Kerr™

Clinical Case

A complicated endodontic retreatment using a new cordless obturation system: a case report

Dr. Garry L. Bey

A complicated endodontic retreatment using a new cordless obturation system: a case report

Dr. Garry L. Bey

D.D.S.

Dr. Garry Bey is in private practice in New York and New Jersey specialising in endodontics. He received his D.D.S. degree and completed his endodontic residency training in endodontics at the NYU College of Dentistry. Dr. Bey lectures both nationally and internationally and has conducted classes with dentists from over 30 countries. He is a member of the American Association of Endodontists, the American Dental Association, the New York State Dental Association, and he is a Past President of the Rockland County Dental Society.

The main objective of endodontic treatment is the prevention and/or the elimination of apical periodontitis. This is achieved by instrumentation, disinfection, and obturation of the root canal system in three dimensions. Gutta-percha is the most widely used and accepted obturation material because of its biocompatibility, inertness, dimensional stability, compactability, plasticity when heated, and ease of removal for post placement or retreatment.[1]

There are a variety of techniques that are used to obturate the root canal system. They can be divided into two basic groups: cold lateral compaction and warm vertical compaction. Warm vertical compaction of gutta-percha using the continuous wave of condensation technique is less time consuming, provides less microbial coronal leakage,[2] and adapts better to grooves and depressions of the canal walls and lateral canals than cold lateral compaction.[3,4]

This case report presents the retreatment of a three-rooted maxillary first bicuspid using the new elementsfree cordless obturation system by Kerr (Fig. 1).

The continuous wave of condensation technique using the elements™free cordless obturation system

This technique allows a single-tapered electric heat plugger to capture a wave of condensation at the orifice of a canal and ride it, without release, to the apical extent by downpacking in a single, continuous movement. Because the tip moves through a viscosity-controlled material into a tapered-like canal form, the velocity of the thermo-softened gutta-percha and sealer moving into the root canal system actually accelerates as the downpacking progresses, moving softened gutta-percha into extremely small ramifications (Figs. 2a, 2b, 3). The continuously tapered root canal preparation facilitates the fit of a suitably sized gutta-percha cone by Kerr (Fig. 4).

The master cone selected should be inserted to full working length and exhibit apical tugback (resistance to displacement) upon its removal. It is simple to fit a master cone into a patent, smoothly tapered, and well-prepared canal.[5-8] The intimacy of diametrical fit between the cone and the canal space may be confirmed radiographically.

The cone may then be trimmed about 0.5 to 1mm from the radiographic terminus so that its most apical end is just short of the working length to accommodate vertical movement of the vertically condensed gutta-percha cone.

The heated plugger of the downpack device (most commonly a .06 or .08 taper with 0.5mm diameter) should fit within 4 to 7mm from the apical terminus to allow full thermo-softening of the apical gutta-percha plug. When the tip of the plugger comes into contact with the dentine (the binding point) in the canal, the rubber stop should be adjusted to its corresponding occlusal reference point (Fig. 5). Stainless steel pluggers may be pre-fit into the canals to their binding point in preparation for the backfilling. Rubber stoppers are adjusted on these pluggers to the occlusal reference point corresponding to 2mm short of the apical binding point. These pluggers are placed aside to be used later in the backfill phase of canal obturation (Fig. 6).

Sealer and master cone placement

The amount of sealer used in this obturation technique should be minimal. The radicular portion of the master cone is lightly covered with sealer and the cone is gently slid to length. Placing the master cone in this manner will serve to distribute sealer more evenly along the walls of the preparation and, importantly, allow surplus sealer to harmlessly vent coronally[5-8] (Fig. 7).

Both the downpack and backfill devices of the elementsfree obturation system may be pre-heated by depressing the "jump start" button, which is located in the centre of the docking station. This will allow a seamless technique with no down time. The downpack handpiece is activated by depressing the activation ring with a gloved finger. The tip will remain heated only as long as the ring is depressed. A "time-out" feature in the elementsfree downpack handpiece assists the clinician by shutting off the energy to the tip after four seconds. This will aid in avoiding overheating of the tooth and/or tissue. The handpiece will need to be reactivated by depressing the activation ring to resume heating beyond the preset duration.

The master cone is seared at the orifice of the canals with the activated heated plugger, and then gently "seated" with a larger stainless steel plugger. The activated heated plugger is driven through the centre of the gutta-percha in a single motion (about one to two seconds), to a point about 3 to 4mm shy of its apical binding point (Figs. 8 and 9). While maintaining pressure on the plugger, the activation ring on the downpack handpiece is released and the plugger will slow its apical movement as the plugger tip cools (about one second) to within 2mm of its apical binding point. After the plugger stops short of its binding point, apical pressure on the plugger is sustained until the apical mass of gutta-percha has set (five to 10 seconds), to minimise any shrinkage that occurs upon cooling (Fig. 10).

Separation burst

After the apical mass has set, the activation ring on the downpack handpiece is depressed again, for a one-second surge of heat. Pause for one second after this separation burst, and then remove the heated plugger and the middle and coronal gutta-percha leaving behind the 4 to 6mm apical plug of gutta-percha (Figs. 11 and 12).

Because these pluggers heat from their tips, this separation burst of heat allows for quick, sure severance of the plugger from the already condensed and set apical mass of gutta-percha, minimizing the possibility of pulling the master cone out. Be certain to limit the length of this heat burst, as the goal is separation from the apical mass of gutta-percha without reheating.


2A

Fig. 1 – The elementsfree Obturation System is a cordless obturation system that is easy to use. The downpack and backfill devices are available to sit in combined or single docking stations that will recharge the batteries.
Figs. 2A/2B – Posttreatment images of a mandibular right second premolar and a maxillary central incisor which illustrates lateral canals exiting into the centres of endodontically induced periradicular lesions. Courtesy of Dr. Gary Glassman, Toronto.
Fig. 2C – Posttreatment image of a maxillary central incisor showing three dimensional obturation of an internally resorptive defect and lateral canal. Courtesy of Dr. Adam Grossman, Toronto.
Fig. 3 – Microcomputed tomography 3D reconstruction of a maxillary molar, illustrating the root canal system's complex anatomy. These areas must be cleaned of their organic debris and bacterial contaminants by thorough irrigation protocols and subsequently three dimensionally sealed with thermo softened gutta-percha. Courtesy of Dr. Ronald Ordinola Zapata, Brazil.

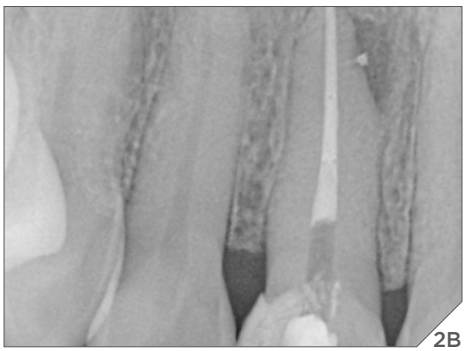
2B

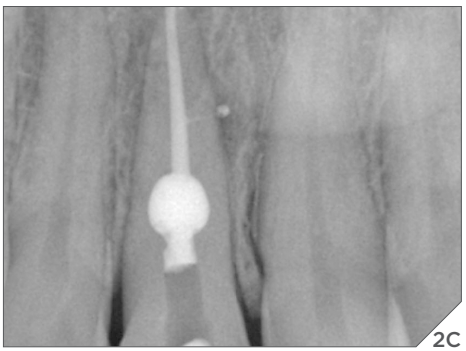
2C

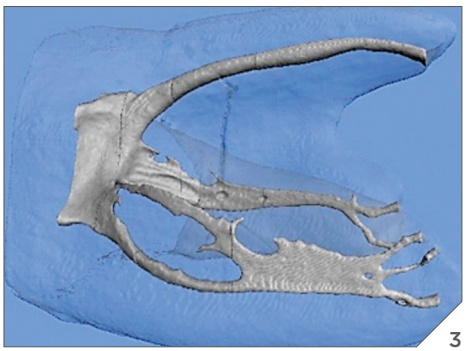
3

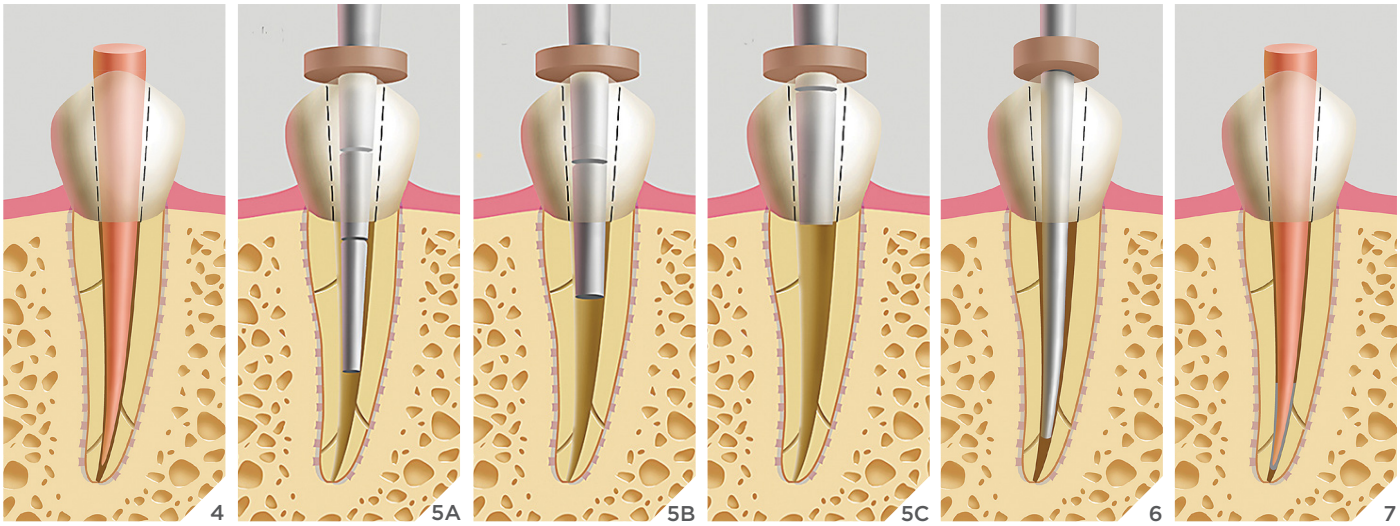

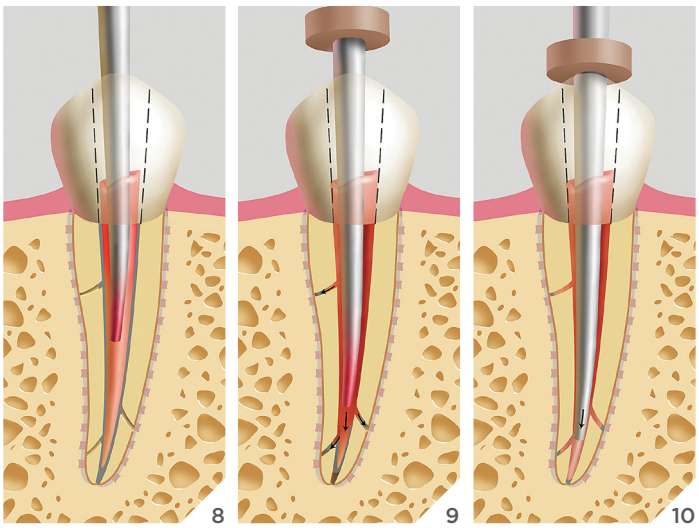

Fig. 4 – Cone Fit. A suitably sized gutta-percha cone is fit into the tapered root canal preparation, making sure that "apical tug-back" has been at working length. The cone is then cut 0.5 to 1mm to accommodate it apical movement (distance from apical reference point will vary with canal curvature and size).
Figs. 5A, 5B, 5C – Heat Plugger fit. It is essential that an appropriate downpack plugger is prefit into each canal to its binding point. A rubber stop must be placed and adjusted to the appropriate coronal reference point for each canal.
Fig. 6 – Stainless steel hand pluggers may be pre-fit into the canals to their binding point. Rubber stoppers are adjusted on these pluggers to the occlusal-reference point corresponding to 2mm short of the apical binding point.
Fig. 7 – The master cone is cemented in the canal with sealer.
Figs. 8/9 – Initiation of downpack. With the activation ring depressed on the elementsfree downpack handpiece, the pre fit, preheated plugger is smoothly driven through the mass of gutta-percha to within 4-6mm of the binding point.
Fig. 10 – Sustained apical condensation. The activation ring should be released once within 3-4mm of the apical binding point. The plugger should slow and stop within 2mm of the binding point. Apical pressure is maintained for a full 10 seconds "sustained" push to prevent the cooling gutta-percha mass shrinking. Once the activation ring is released an internal clock counts down within the downpack device. At 5 seconds there will be an audible single "chirp". At 10 seconds there will be an audible double "chirp".

Clinicians must be very alert during the first second of the downpack so that the binding point is not reached before completion of the downpack. If heat is held for too long, the plugger drops to its binding point in the canal and then cannot maintain condensation pressure on the apical mass of gutta-percha during cooling, possibly allowing it to pull away from the canal walls. If binding length is reached by mistake, the heat plugger should be removed immediately and the small end of the nickel-titanium end of a Buchanan hand plugger (Kerr) may be used to condense the apical mass of gutta-percha until set.

Backfilling

The elementsfree backfill handpiece accommodates disposable preloaded cartridges of gutta-percha of varying densities. The applicator tips are available in 23-gauge and 25-gauge diameters. The combinations are as follows: 23-gauge medium body, 23-gauge heavy body or 25-gauge light body.

There is enough gutta-percha in the disposable cartridges to fill an average four-canal molar. The author prefers to use the heavy body gutta-percha and a 23-gauge applicator tip as they are suitable for most canals treated. The applicator tip is placed into the root canal space until it penetrates the coronal aspect of the apical plug of gutta-percha for five seconds to thermo-soften its most coronal extent again. This procedural nuance promotes cohesion between each injected segment of warm gutta-percha and the apical plug so the two will seamlessly integrate; segments to of 5 to 6mm of gutta-percha are then deposited. Injecting or dispensing too much gutta-percha may lead to cooling shrinkage and/or voids, which result in poorly obturated canals within the deeper confines of the root canal space.[8] As gutta-percha is extruded from the applicator tip, the viscosity gradient of the back pressure produced will push the tip coronally from the root canal space. The technique sensitivity requires that when this sensation occurs, the operator must sustain pressure on the activation button mechanism as the applicator tip moves from the canal. The stainless steel or nickel titanium ends of the Buchanan hand pluggers are then used in sequence to maximise the density and homogeneity of the compressed gutta-percha mass. This sequence of thermo-softened gutta-percha injection and progressive compaction is continued until the obturation of the entire root canal space is achieved. (Figs. 13-19)

Case Report

A 24 year old Caucasian female with a history of pain was referred for evaluation and retreatment of tooth #24. Tooth #24 had root canal treatment previously performed by a general dentist approximately three months prior to being seen in our office. Upon initial exam, a preoperative intraoral digital radiograph (Dexis, Alpharetta, GA) showed that this maxillary first bicuspid had three roots (Fig. 20). The mesiobuccal and palatal canals appeared to have been

adequately filled. The distobuccal canal was filled short. A cone beam computed tomography scan (CBCT) of the left maxilla was performed with limited FOV at 76µm (Kodak 9000; Carestream Dental, Atlanta, GA) and revealed the distobuccal root with periapical pathology (Fig. 21) and a patent canal (Fig. 22). Clinically, there was leakage around the temporary filling. The treatment plan decided and ultimately agreed upon was endodontic retreatment of all three canals.

Appointment one

Access was made through the temporary filling with a number 6 surgical length round bur in a slow speed handpiece. The gutta-percha from all three canals was removed and a glide path was created from orifice to apex using hand files. The canals were instrumented to the apex to a size .04/35 Twisted File used in an Elements Motor (Fig. 23) using Adaptive Motion (Kerr).

Calcium hydroxide was placed in each canal with a lentulo spiral, a sterile cotton pellet was placed in the pulp chamber and the access cavity was sealed with Cavit W (3M ESPE). The occlusion was reduced. The patient was prescribed Amoxicillin 500mg, dispense 30, sig: 1TID.

Appointment two

The temporary restoration was removed with a number 6 surgical length round bur in a slow speed handpiece and the mesiobuccal and distobuccal canals were enlarged to a 45 LSX LightSpeed file (Kerr) to their apices. The palatal canal was enlarged to a 50 LSX LightSpeed file to its apex. A final irrigation protocol was performed using apical negative pressure employing the EndoVac (Kerr).

The protocol suggested uses three irrigation cycles. The first cycle uses sodium hypochlorite 5.25 percent, followed by a second cycle using 17 percent EDTA, followed by a third and final cycle using 5.25 percent sodium hypochlorite. The canals were then dried and obturated using the continuous wave of condensation technique with the cordless elementsfree cordless obturation system (Kerr) (Fig. 25).

Discussion

The objective of endodontic obturation is the total three-dimensional filling of the root canal system and all of the lateral and accessory canals associated with it. Brothman[9] demonstrated that vertical compaction of warm gutta-percha approximately doubled the number of filled lateral canals compared with lateral compaction of gutta-percha The warm vertical technique has shown greater ability

Figs. 11/12 – Separation burst. The downpack activation ring is depressed for one second then released. The plugger is held in position for one second after the button is released, and the plugger is then removed with the surplus gutta-percha coronal to the apical plug adhering to the cooling plugger, leaving the apical seal intact. All portals of exit may be sealed, primarily with gutta-percha or a combination of gutta-percha and sealer, and the canal is ready for backfilling.
Figs. 13-19 – Backfilling. Applicator tips for the elementsfree cordless obturation system are available in sizes numbers 20, 23, and 25 gauges. Additional root canal sealer may be placed in the coronal aspect of the root canal with a hand file prior to back filling. 4 to 6mm increments of gutta-percha are injected into the canal space then immediately condensed with the pre-fitted stainless steel hand pluggers in sequence using the sequentially larger pluggers as the coronal aspect of the canal is approached. As thermo-softened gutta-percha is deposited in the canal, back pressure is produced and the applicator is forcibly extruded from the canal space. It is essential that the operator continues injecting as the applicator tip is retrieved from the canal in order to avoid inadvertent removal of the newly deposited gutta-percha mass prior to condensation.

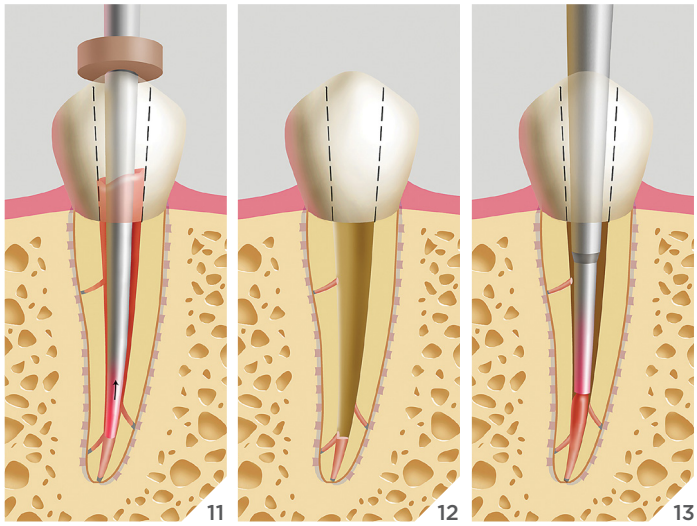

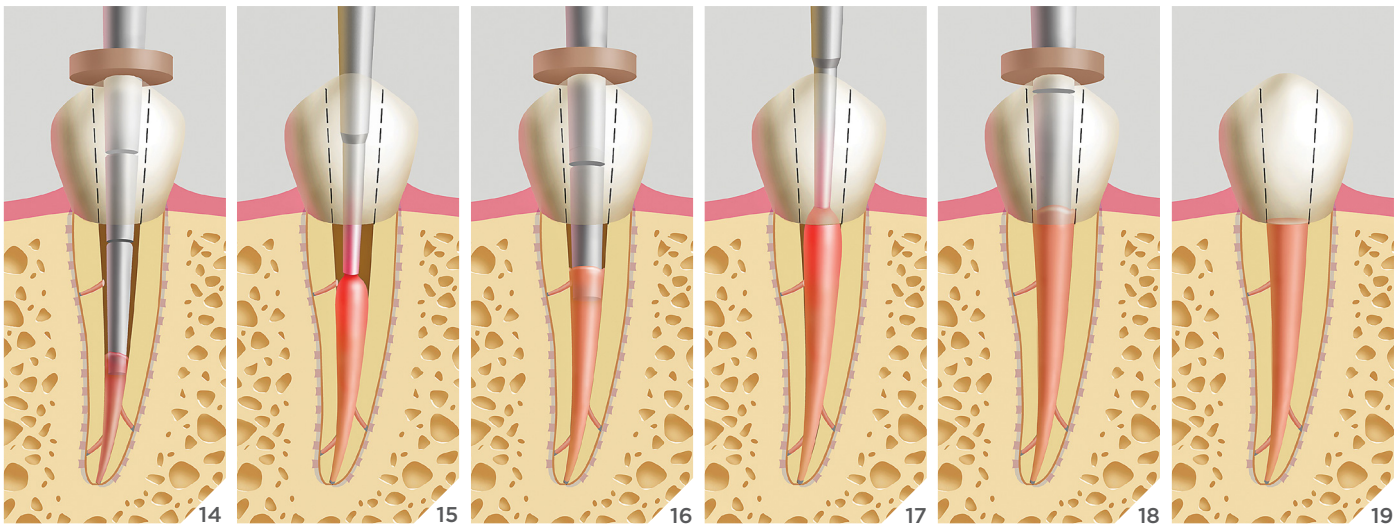

to flow into canal irregularities than the cold lateral technique.[10,11] Warm vertical compaction was first introduced by Schilder[12] in 1967. With this method, gutta-percha is heated and packed in three to five interrupted waves of compaction. In contrast, the continuous wave of condensation technique was introduced with the goal of simplifying traditional vertical compaction.[13] This technique allows a single tapered electric heat plugger to capture a wave of compaction pressure at the orifice of a canal and ride it, without release, to the apical extent of the downpack in a single, continuous movement.[14] The remainder of the canal is then filled with a backfill device. Endodontic retreatment presents the clinician with many challenges. Among them are the removal of posts, cores, foreign objects and root canal filling materials that might be within the root canal system. Once this is attained, the root canal system is prepared, disinfected, and obturated. In this case obturation was accomplished using the cordless elementsfree obturation system (Kerr Endodontics). The cordless feature allows freedom of movement during treatment. The omnidirectional activation ring on the downpack unit is easily depressed, independent of the position of the plugger in the canal. The swivel movement of the needle tips and the extrusion action of the backfill device make delivery of gutta-percha efficient, easy and precise, leaving no voids in the final outcome.

Conclusion

Although maxillary first bicuspids with three roots do exist both in the literature and in practice, they are rare. Retreatment of a tooth with this type of anatomy is a perfect example of why proper instrumentation followed by efficient irrigation leads to superb obturation. A new elementsfree cordless obturation system was used in this case. Its ease of use and efficiency provide a promising advance in the field of endodontic obturation.

References available upon request.

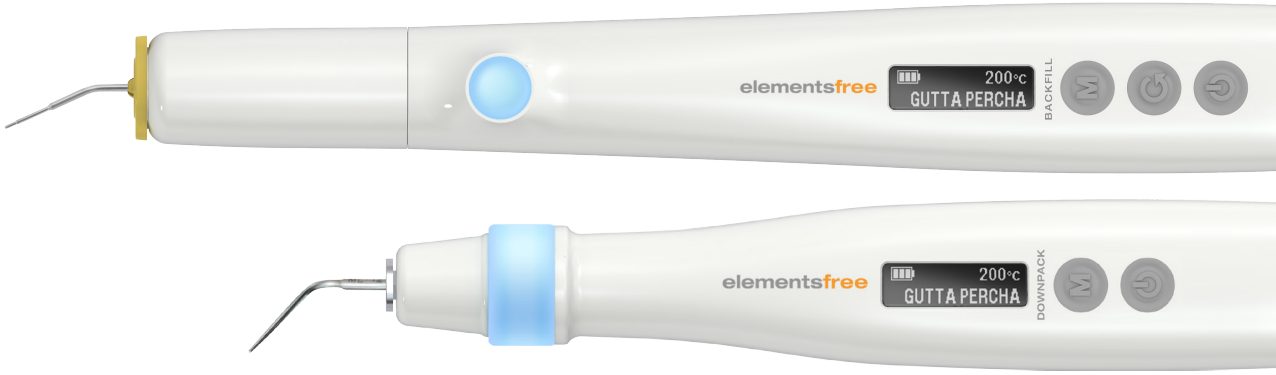

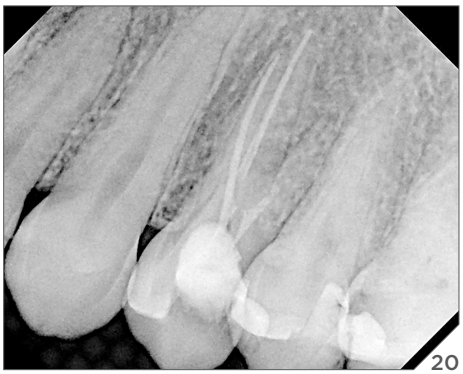

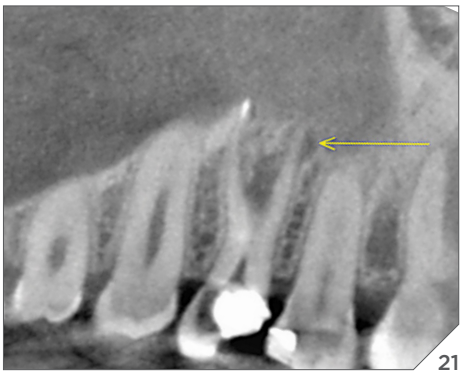

Fig. 20 – Tooth number 24 initial preoperative periapical radiograph.
Fig. 21 – Tooth number 24 CBCT sagittal view–periapical pathology distobuccal root.
Fig. 22 – Tooth number 24 CBCT axial view patent distobuccal canal.
Fig. 23 – Elements Motor. The Elements™ Motor (Kerr) is a multisetting motor used for automated NiTi instrumentation. In TF Adaptive mode, there is a continuous feedback loop from the file to the motor and back to the file, where the motion of the file self-adjusts to the intracanal torsional stresses. The file will rotate when there is no or minimal load on the file (channelling debris out coronally), and reciprocates when there is load on the file (increasing the resistance of the file to cyclic fatigue).
Fig. 24 – Tooth number 24 post-op radiograph. Root canal retreatment completed.